

Nonsurgical treatment of skeletal anterior open bite in adult patients: *Posterior build-ups*

Arturo Vela-Hernández^a; Rocio López-García^b; Verónica García-Sanz^c;
Vanessa Paredes-Gallardo^d; Felicidad Lasagabaster-Latorre^b

ABSTRACT

Objective: To (1) evaluate the efficacy of build-ups in the correction of anterior open bite in adults, (2) evaluate their efficacy in producing molar intrusion, (3) analyze skeletal and dental changes, and (4) assess the long-term stability.

Materials and Methods: The sample consisted of 93 lateral cephalograms from 31 patients with skeletal and dental anterior open bite. The patients had received orthodontic treatment consisting of bonded resin blocks on the maxillary molars combined with Tip-Edge Plus bracket appliances. Cephalometric measurements were performed on radiographs taken before treatment (T1), after treatment (T2), and after a retention period (T3), which were analyzed and compared.

Results: Significant dental and skeletal changes were observed after treatment. Molar intrusion averaging 1 mm; 1.44 and 1.57 mm extrusion of mandibular and maxillary incisors, respectively; and a mean of 3.98 mm overbite increase were observed. The mandibular plane angle showed a mean closure of 1.19°, and there was a mean decrease in anterior facial height of 0.7 mm. A mild relapse tendency was observed, but long-term stability was acceptable.

Conclusions: Build-ups are an effective treatment alternative for anterior open bite in adults. Outcomes remain significantly stable during the retention period. (*Angle Orthod.* 2017;87:33–40)

KEY WORDS: Open bite; Build-up; Molar intrusion

INTRODUCTION

Anterior open bite (AOB) malocclusion, defined as a lack of vertical overlap or contact between the maxillary and mandibular incisors, is of multifactorial etiology.¹ Its prevalence varies between ethnic groups, age, and dentition, ranging from 1.5% to 11%²; it can be classified as a dentoalveolar or skeletal malocclusion.³ Individuals presenting with skeletal AOB generally combine increased gonial, mandibular, and occlusal

plane angles; increased mandibular and anterior facial height (AFH); mandibular retrusion; short mandibular body and ramus; divergent cephalometric planes; steep anterior cranial base⁴; and difficulty with labial seal.⁵ Due to its multifactorial etiology and high tendency to relapse,^{4,6} skeletal AOB in adults is regarded as one of the most challenging malocclusions to treat.⁷

Although most of the studies about treatments available report good outcomes, the real success of AOB therapy should be measured by its long-term stability.⁸ Some studies with long-term follow-up periods indicate that both surgical and nonsurgical treatments close the AOB effectively, but are prone to some relapse⁹ in the first years of retention.^{4,6,10}

Orthodontists usually obtain bite closure by combining incisor extrusion or uprighting and molar intrusion, ideally obtaining a counterclockwise rotation of the mandibular and occlusal planes.

Orthodontic treatment with multiloop archwires has been reported to intrude posterior teeth and to extrude the anteriors. This approach does not produce significant changes in the skeletal pattern, whereas it does produce remarkable dental changes.^{11,12} Carano et al.¹³

^a Adjunct Professor, Department of Orthodontics, University of Valencia, Valencia, Spain.

^b Private Practice, Vitoria, Spain.

^c Assistant Professor, Department of Orthodontics, University of Valencia, Valencia, Spain.

^d Associate Professor, Department of Orthodontics, University of Valencia, Valencia, Spain.

Corresponding author: Dr Verónica García-Sanz, Department of Orthodontics, University of Valencia, Ortodoncia 5^a Planta, Clínica Odontológica UV, C/Gascó Oliag n^o1, Valencia, Valencia 46010 Spain (e-mail: veronique_hd@hotmail.com)

Accepted: May 2016. Submitted: March 2016.

Published Online: July 19, 2016.

© 2017 by The EH Angle Education and Research Foundation, Inc.

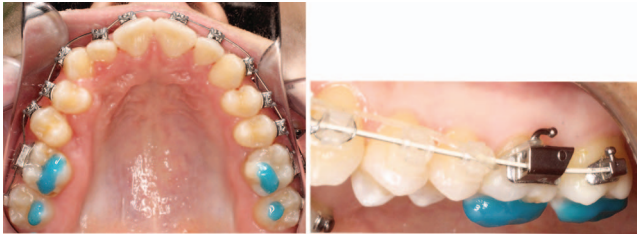

Figure 1. Occlusal and lateral views of resin build-ups.

described a technique consisting of rapid molar intrusion (RMI), obtaining significant skeletal changes in nongrowing patients.

Another common approach that has been used in the past few years is skeletal anchorage devices such as miniscrews¹⁴ or miniplates.¹⁵ These therapies can be used for molar intrusion.^{16,17} Both dental and skeletal changes take place.¹⁵

Extraction of molars or premolars has been proposed as an alternative for treating AOB malocclusions by moving posterior teeth forward in an attempt to achieve an anticlockwise rotation of the mandible.¹⁸

Orthognathic surgery for correcting AOB malocclusion consists in performing a LeFort I osteotomy and, in some cases, mandibular ramus osteotomy, which repositions the maxilla allowing the counterclockwise rotation of the mandible.¹⁹

Posterior removable bite blocks are also an effective option, which intrude and control eruption of the posterior teeth.²⁰

Resin blocks bonded to the posterior teeth (build-ups) could be an advantageous AOB treatment option as they are a noninvasive technique and do not require patient cooperation. Only one study has described the technique and provided indications for posterior build-ups, which unblock the occlusion and induce molar intrusion; this allows the counterclockwise rotation of the mandible and an improved vertical anterior relation. However, the study did not investigate cephalometric changes.²¹ Given the lack of research into skeletal AOB correction with noninvasive techniques in adults, there is a clear need to test the efficacy of this therapy.

For this reason, the purposes of this study were to (1) evaluate the efficacy of build-ups for correcting skeletal AOB in adults, (2) evaluate their efficacy for inducing molar intrusion, (3) analyze dentoalveolar and skeletal changes after build-up therapy, and (4) assess the long-term stability of this treatment option.

MATERIALS AND METHODS

This descriptive, retrospective human study was designed to follow STROBE guidelines and compliance with the Declaration of Helsinki involving human subject guidelines. The study protocol was approved

by the University of Valencia Ethics Committee for Human Research (H1450127854234). All patients whose records were used in the study received detailed information and gave their informed consent to take part.

Patients

Seventy-five patients attending a private dental clinic between 2012 and 2014 who had been diagnosed with AOB were selected. Power analysis showed that a sample size of at least 30 patients would provide an 85% probability of detecting a medium effect ($f = 0.25$) between time points, using an ANOVA model at a confidence level of 95% and assuming a correlation among repeated measurements of 0.5.

Inclusion criteria were as follows:

- Nongrowing patients. Lateral cephalograms of the patients were analyzed to assess skeletal growth using the cervical vertebral maturation method.²²
- Anterior open bite of 1 mm or greater, determined on lateral cephalograms by measuring the distance between the maxillary and mandibular incisal edges on a line perpendicular to the occlusal plane.
- Skeletal open bite. Patients with a palatal-mandibular plane angle over 22° , as measured on lateral cephalograms, were included.²³
- Patients treated without extractions.
- Patients with good quality lateral cephalograms before treatment, after treatment, and 12 or more months after treatment.
- Skeletal Class I ($ANB 2^\circ \pm 1^\circ$)

After the inclusion criteria were applied, 31 patients were selected, 14 (45.17%) women and 17 (54.83%) men, being a homogeneous distribution; a total of 93 lateral cephalograms were available for analysis. The mean age of the sample was 26.6 ± 4.9 years, ranging between 22.1 and 32.6 years.

Method

All patients had been treated using fixed Tip-Edge Plus (TP Orthodontics Inc, La Porte, Ind) bracket appliances, overexpanded archwires, and posterior fixed resin blocks. Build-ups of 2–3 mm were cemented during the first treatment stage on the functional cusps of all maxillary molars to maintain natural occlusal forces (Figure 1). Cusp surfaces were etched (Total Etch, Ivoclar Vivadent, Schaan, Liechtenstein) and Ultra Band-Lock (Reliance Orthodontic Products, Inc, Itasca, Ill) was used for the resin build-up.

At this stage, 0.014-inch superelastic nickel-titanium (SE NT) archwires were applied to level and align the maxillary and mandibular arches, followed by 0.016 × 0.025-inch SE NT archwires to define the

Table 1. Cephalometric Hard Tissue Landmark Abbreviations and Definitions Used in the Study

Landmark	Abbreviation	Definition
1 Sella	S	Point situated in the middle of sella turcica
2 Nasion	N	Most anterior part of the frontonasal suture
3 Gnathion	Gn	Most anteroinferior point on the outline of the chin
4 Gonion	Go	Most posteroinferior point on the angle of the mandible
5 Menton	Me	Lowest midline point on the mandibular symphysis
6 Anterior nasal spine	ANS	Tip of the osseous anterior nasal spine
7 Posterior nasal spine	PNS	Tip of the osseous posterior nasal spine

arch shape and level the occlusal plane, while build-ups kept working. Stainless steel 0.021 × 0.028-inch archwires combined with 0.016-inch SE NT archwires, introduced through the auxiliary slot, were placed to achieve the correct torque and tipping. Then the build-ups were removed. Finally, 0.016-inch SE NT archwires combined with posterior vertical elastics were placed for optimal interdigitation. Anterior elastics were not used at any stage. All appliances were removed and maxillary and mandibular canine-to-canine fixed lingual retainers were bonded. Maxillary and mandibular clear removable retainers, adjusted to avoid anterior occlusal contacts, were given to the patients for night use.

Total treatment duration was a mean of 17.2 months (SD 4.2, range 12–28 months), and build-ups were used for a mean of 14.2 months (SD 4.4, range 9–21 months).

Cephalometric Analysis

Three lateral cephalometric radiographs were obtained for each patient: before treatment (T1), after treatment (T2), and during the retention period (T3). The mean retention period was 32.9 months (SD 21.5 with a range of 12–82 months).

Seven cephalometric landmarks were identified on each radiograph (Table 1 and Figure 2a) and 11 skeletal and dental measurements were taken (Table 2 and Figure 2b) by a single observer who had been fully trained and calibrated. A total of 1023 measurements were registered.

T1, T2, and T3 measured radiographs for each patient were superimposed to (1) assess the changes produced by orthodontic treatment (T2–T1) and (2) assess the changes that had taken place during the period T3–T2. All cephalometric measurements were taken using Nemoceph 11.3.1 software (Nemotec, Madrid, Spain).

Arch Analysis

Patients' plaster models were measured to assess initial crowding, obtaining an average discrepancy of –3 SD 1.1 mm in the maxillary arch and –3.5 SD 1.8 mm in the mandibular arch.

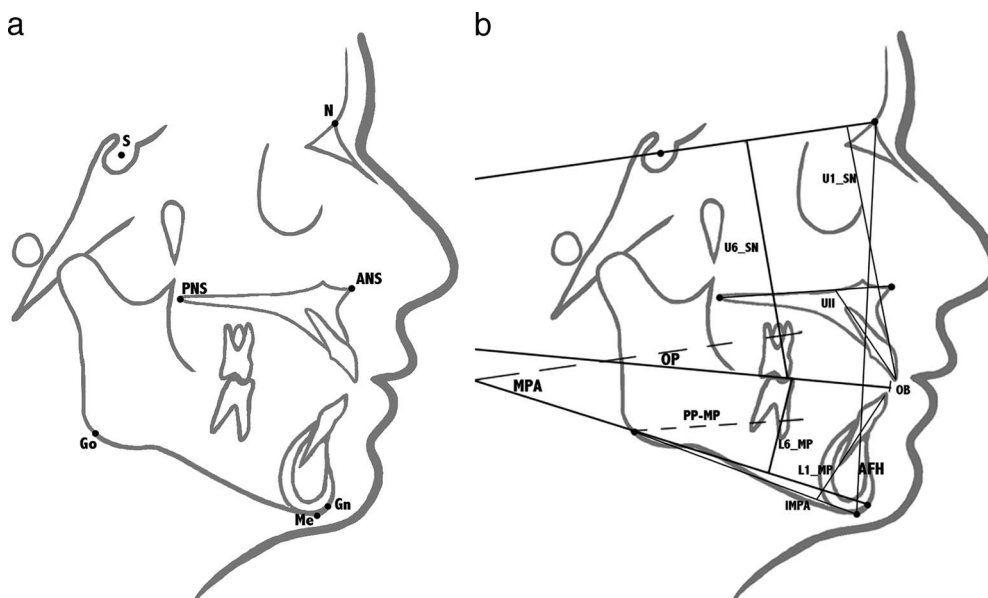
**Figure 2.** (a) Cephalometric landmarks used in the study; (b) skeletal and dental measurements.

Table 2. Osseous and Dental Cephalometric Measurement Abbreviations and Definitions Used in the Study

Landmark	Abbreviation	Definition	Norm
Osseous			
Mandibular plane angle (Steiner)	MPA	Angular landmark. Angle formed by the intersection of mandibular plane (Go-Gn) and SN	32° ± 4°
Occlusal plane angle (Steiner)	OP	Angular landmark. Angle formed by the intersection of occlusal plane and SN	14° ± 2°
PP-MP angle	PP-MP	Angular landmark. Angle formed by the intersection of PP and MP	22° ± 4°
Anterior facial height	AFH	Linear landmark. Distance in mm between nasion and menton	Norm 105–120 mm
Dental			
Overbite	OB	Linear landmark. Distance in mm between maxillary and mandibular incisal edges perpendicular to the occlusal plane	2 mm
Mandibular incisor inclination	IMPA	Angular landmark. Angle formed by the intersection of mandibular incisor (A ₁) and mandibular plane (Me-Go)	90° ± 2.5°
Maxillary incisor inclination (Burstone)	UII	Angular landmark. Angle formed by the intersection of maxillary incisor (A1) and palatal plane (ANS-PNS)	112°–117°
Mandibular molar intrusion	L6-MP	Linear landmark. Perpendicular distance in mm between mesiobuccal cusp of mandibular first molar and mandibular plane (Go-Gn)	No norm
Mandibular incisor extrusion	L1-MP	Linear landmark. Perpendicular distance in mm between mandibular incisal edge and mandibular plane (Go-Gn)	No norm
Maxillary molar intrusion	U6-SN	Linear landmark. Perpendicular distance in mm between mesiobuccal cusp of maxillary first molar and sella-nasion plane (SN)	No norm
Maxillary incisor extrusion	U1-SN	Linear landmark. Perpendicular distance in mm between maxillary incisal edge to sella-nasion plane (SN)	No norm

Statistical Analysis

Intra- and interobserver error was calculated by coefficients of variation ($CV = SD \times 100/\text{mean}$, expressed as percentages) and by the Dahlberg formula. All lateral radiographs (93) were traced and measured again 1 week later by the principal observer and by a second calibrated observer.

Data obtained from cephalometric measurements were entered on a spreadsheet, using Microsoft Excel 2011 (Microsoft Corp, Redmond, Wash). Study variables were the skeletal and dental measurements (both lineal and angular) at T1, T2, and T3. Descriptive statistics were calculated for each parameter, as well as the differences between times T2–T1, T3–T2, T3–T1: mean, standard deviation, minimum, maximum, and median. Differences between times represented the effect of treatment (T2–T1), relapse (T3–T2), and long-term overall effect (T3–T1). Normality of measurement differences was checked by the Kolmogorov-Smirnov test, obtaining a confirmatory result ($P > .05$) for all parameters. A linear model repeated-measures ANOVA was used to evaluate the effects of treatment at different times. The least significant difference test (LSD) was used for multiple comparisons. Pearson's correlation coefficient was applied to evaluate linear associations between T2–T1 effects for different parameters. The level of significance was established at 5% ($P = .05$).

RESULTS

Intra- and interobserver error was appropriate: *d* of Dahlberg values was under 0.28 and CVs were below 2.55% in all cases.

Measurements taken at T1, T2, and T3 are shown in Table 3 and Figure 3. ANOVA was used to determine whether differences between times were statistically significant.

Statistically significant correction of anterior open bite was observed in all patients. Mean overbite increase was 3.98 mm at the end of treatment (T2) and relapsed just 0.56 mm at T3.

Correction was achieved by maxillary molar intrusion, maxillary and mandibular incisor extrusion, and counterclockwise rotation of the mandible.

Dental and skeletal changes are shown in Table 3. Mean mandibular incisor extrusion was 1.44 mm at the end of treatment (T2), and showed a mean 0.2 mm relapse at T3, both changes being significant. Average extrusion of maxillary incisors was 1.57 mm at the end of treatment (T2), a significant change, and presented an 0.08 mm relapse at T3, which was not significant.

Maxillary molar intrusion was statistically significant (1.5 mm at the end of treatment; T2–T1), which remained stable from T2 to T3, showing a relapse of only 0.10 mm. All the skeletal measurements showed a statistically significant decrease at the end of treatment, confirming counterclockwise rotation of the

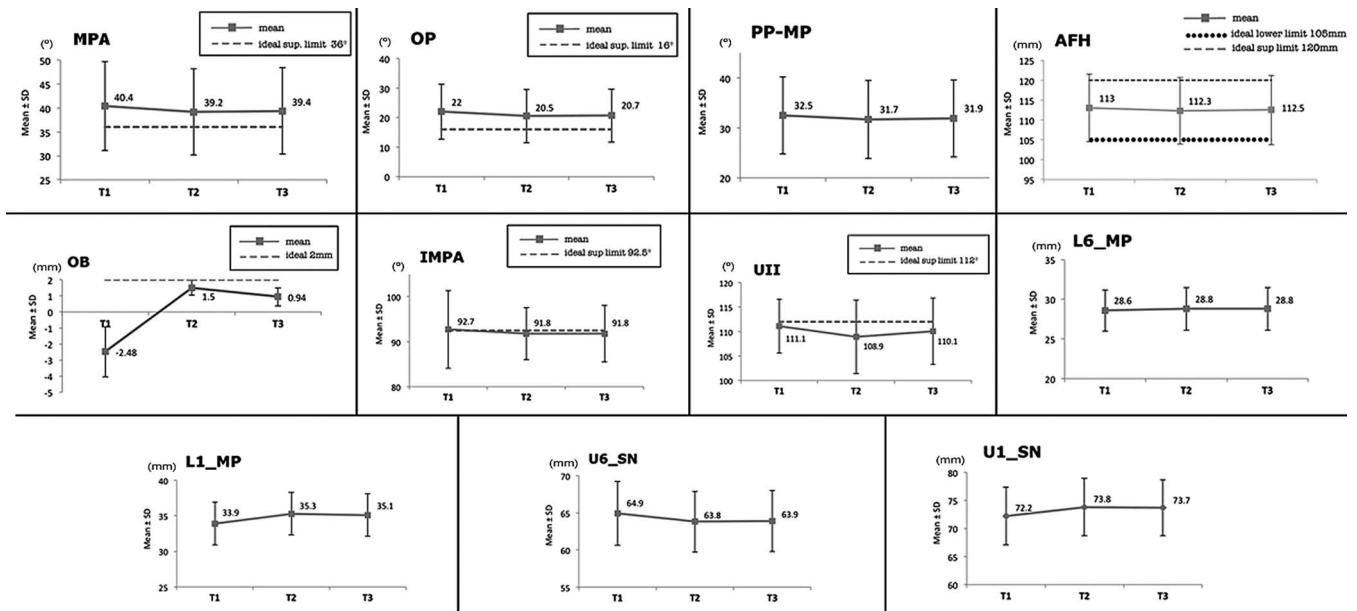


Figure 3. Measurement evolution between T1, T2, and T3.

mandible. The mandibular plane angle, PP-MP, and occlusal plane angle showed average decreases of 1.53°, 0.84°, and 1.53°, respectively, at the end of treatment (T2–T1), with statistical significance.

Pearson's correlation coefficient was used to determine whether any parameter variation between T1 and T2 was related to any other parameter variation. Table 4 shows the correlation coefficients and statistical significance of each pair. Overbite correction was significantly related to mandibular incisor extrusion and the mandibular plane, while the mandibular plane was also correlated with the occlusal plane and to mandibular incisor extrusion. Lastly, the occlusal plane was correlated with mandibular molar extrusion and mandibular incisor extrusion.

DISCUSSION

The present study's chief finding was that the use of build-ups on maxillary molars offers a simple and effective alternative approach to correcting AOB, intruding maxillary molars and so inducing counterclockwise mandibular rotation with consequent bite closure.

The patients selected for the study were nongrowing individuals, which avoided any distortion of the results arising from growth changes. All patients presented a skeletal Class I occlusion, making the sample as homogeneous as possible. The results do not specify patient sex, as gender distribution was also homogeneous. All patients presented skeletal open bite, confirmed by the PP-MP measurement.

Intra- and interobserver method reproducibility was seen to be very high, and the error observed was

small, showing very low coefficient of variation and d of Dahlberg values.

To assess changes resulting from treatment with build-ups, lateral cephalometric radiographs were used, this being a widely used method for assessing molar intrusion and other dental and skeletal changes.^{12–15}

Dental and skeletal parameters at T1, T2, and T3 were compared and the differences between times were analyzed. Regarding dental changes, overbite increased by 3.98 mm after treatment (T2), a statistically significant increase and a finding similar to the changes observed by Erverdi et al.¹⁵ and Hart et al.,¹⁴ who used skeletal anchorage (miniplates and microscrews, respectively) for molar intrusion. Studies of the RMI device¹³ and the multiloop technique¹² show less satisfactory results than does the present study, in which mandibular incisor average extrusion of 1.44 mm contributed to the overbite increase. This change has been associated with the leveling effect produced by the archwires. The present results match findings by Endo et al.¹² (1.5 mm).

Maxillary molar intrusion also contributed to bite closure. In the present study, the SN and MP planes were used as references to evaluate the evolution of molar height since they are very stable and reproducible planes. A mean of 1.15 mm intrusion was obtained as a consequence of treatment with posterior build-ups with statistical significance. Contrary to the present results, researchers using multiloop archwire systems have not found significant changes in maxillary molar vertical positions.^{11,12} The maxillary molar intrusion obtained using skeletal anchorage has been found

Table 3. Total Measurements: T1, T2, T3, Mean, Standard Deviations (SD), Minimum/Maximum, and Median^a

Measurements	T1			T2			T3		
	Mean ± SD	Min/ Max	Median	Mean ± SD	Min/ Max	Median	Mean ± SD	Min/ Max	Median
Dental									
OB ^b (mm)	-2.48 ± 1.57	-8.00/ -1.00	-2.00	1.50 ± 0.47	1.00/ 2.00	1.50	0.94 ± 0.57	0.00/ 2.00	1.00
L6-MP (mm)	28.61 ± 2.61	25.50/ 37.00	28.00	28.77 ± 2.71	25.50/ 37.00	28.50	28.77 ± 2.71	25.50/ 37.00	28.50
U6-SN (mm)	64.94 ± 4.26	57.50/ 74.50	65.00	63.79 ± 4.06	56.00/ 72.50	64.00	63.89 ± 4.07	56.00/ 72.50	64.00
L1-MP (mm)	33.87 ± 3.02	29.00/ 40.50	33.00	35.31 ± 3.02	31.00/ 43.00	35.00	35.05 ± 3.00	31.00/ 42.00	35.00
U1-SN (mm)	72.21 ± 5.09	63.00/ 82.00	71.00	73.77 ± 5.07	65.00/ 84.00	73.50	73.69 ± 5.00	65.00/ 83.50	74.00
IMPA (°)	92.73 ± 8.64	82.00/ 116.00	90.00	91.76 ± 5.78	82.00/ 103.00	91.00	91.76 ± 6.28	80.00/ 103.50	92.00
UII (°)	111.05 ± 5.51	103.00/ 125.00	110.00	108.85 ± 7.45	95.20/ 122.50	111.00	110.08 ± 6.81	100.00/ 122.50	111.00
OP (°)	22.03 ± 6.96	12.50/ 37.00	21.00	20.50 ± 6.09	9.00/ 31.00	22.00	20.68 ± 6.24	9.00/ 31.00	22.00
Skeletal									
MPA (°)	40.38 ± 9.29	25.50/ 55.00	42.00	39.19 ± 8.98	24.00/ 53.00	40.00	39.36 ± 9.04	24.00/ 53.00	40.00
PP-MP (°)	32.50 ± 7.71	24.00/ 46.00	30.00	31.66 ± 7.76	22.00/ 45.00	30.00	31.89 ± 7.74	22.00/ 45.00	30.00
AFH (mm)	113.00 ± 8.49	98.50/ 132.50	113.50	112.31 ± 8.38	98.50/ 132.00	112.50	112.48 ± 8.31	100.00/ 132.00	112.50

^a Level of significance of LSD post hoc test for repeated measures ANOVA model (* $P < .05$; ** $P < .01$; *** $P < .001$).

^b OB indicates overbite; L6-MP, mandibular molar intrusion; U6-SN, maxillary molar intrusion; L1-MP, mandibular incisor extrusion; U1-SN, maxillary incisor extrusion; IMPA, mandibular incisor inclination; UII, maxillary incisor inclination; OP, occlusal plane angle; MPA, mandibular plane angle; PP-MP, palatal plane and mandibular plane angle; AFH, anterior facial height.

greater (approximately 2.6 mm) than that obtained in the present study.¹³⁻¹⁵

As for skeletal changes, the present study obtained an average of 1.19° mandibular counterclockwise rotation, a finding that agrees with Aras et al.,¹⁸ who carried out extractions. In terms of mandibular plane rotation, Erverdi et al.¹⁵ obtained higher values. However, studies of multiloop techniques^{11,12} have not observed any differences in the mandibular plane after treatment. The present study also observed significant changes in AFH after treatment.

Statistically significant changes were also found in the rotation of the occlusal plane angle, with a mean decrease of 1.53°, indicating counterclockwise rotation, which has been associated with both incisor extrusion and mandibular plane rotation. Contrary to the present findings, Erverdi et al.¹⁵ and Hart et al.¹⁴ observed a clockwise rotation of the plane.

Many of the studies reviewed here analyzed results obtained only immediately after removal of orthodontic appliances; only a few monitored long-term retention.^{12-15,18} It is not possible to assess the real success of AOB treatment unless long-term stability is evaluated, as relapse often occurs during the first years of

retention.^{4,6,10} In the present study, measurements were taken before and immediately after treatment, and also some years after treatment (after an average of 32.9 months and never less than 12 months).

In 2002, Huang⁸ pointed out that there were very few studies analyzing treatment stability, sample sizes were small, and the definition of open bite, as well as the methods of assessing success and stability, differed greatly between studies. In our study, retention period values have been included, sample size was adjusted for power analysis calculation, and the study focused on the most commonly used measurements found in the literature, so that it was possible to assess treatment outcomes accurately and compare them with other research.

A minor tendency to relapse was observed among the patients at T3. Maxillary molar intrusion showed a 0.1-mm relapse and the mandibular plane a 0.17° relapse, in agreement with Deguchi et al.⁶ and Baek et al.¹⁰

Some of the methods used for AOB correction described in the literature are either invasive (mini-plates, miniscrews, extractions) or require patient collaboration (removable bite-blocks). The therapy

Table 4. Coefficient *r* of Pearson's Linear Correlations and *P* Values^a

	OB ^b T2-T1	OP T2-T1	MPA T2-T1
OP T2-T1	$r = -0.299$ ($P = .102$)		
MP T2-T1	$r = -0.571$ ($P = .001^{**}$)	$r = 0.357$ ($P = .049^*$)	
L6-MP T2-T1	$r = -0.152$ ($P = .414$)	$r = -0.551$ ($P = .001^{**}$)	$r = -0.228$ ($P = .217$)
L1-MP T2-T1	$r = 0.722$ ($P < .001^{***}$)	$r = -0.598$ ($P < .001^{***}$)	$r = -0.670$ ($P < .001^{***}$)
U6-SN T2-T1	$r = -0.026$ ($P = .889$)	$r = -0.224$ ($P = .225$)	$r = 0.268$ ($P = .145$)
U1-SN T2-T1	$r = 0.156$ ($P = .403$)	$r = 0.234$ ($P = .206$)	$r = 0.087$ ($P = .641$)

^a Statistically significant differences: * $P < .05$; ** $P < .01$; *** $P < .001$.

^b OB indicates overbite; L6-MP, mandibular molar intrusion; U6-SN, maxillary molar intrusion; L1-MP, mandibular incisor extrusion; U1-SN, maxillary incisor extrusion; U1-SN, maxillary incisor inclination; OP, occlusal plane angle; MPA, mandibular plane angle.

Table 3. Extended

T2–T1			T3–T2			T3–T1		
Mean	SD	Median	Mean	SD	Median	Mean	SD	Median
3.98 ± 1.66 ***	2.00/ 9.50	4.00	–0.56 ± 0.60 ***	–2.00/ 0.00	–0.50	3.42 ± 1.62 ***	8.00/ 1.62	3.00
0.16 ± 0.37 *	–0.50/ 1.00	0	0.00 ± 0.00	0.00/ 0.00	0	0.16 ± 0.37 *	–0.50/ 1.00	0
–1.15 ± 0.45 ***	–2.00/ 0.50	–1.00	0.10 ± 0.24 *	0.00/ 1.00	0	–1.05 ± 0.57 ***	–2.00/ 0.00	–1.00
1.44 ± 1.22 ***	–1.00/ 3.00	1.50	–0.26 ± 0.44 **	–1.00/ 1.00	0	1.18 ± 1.07 ***	–1.00/ 2.50	1.50
1.57 ± 1.01 ***	–0.20/ 3.50	1.50	–0.08 ± 0.58	–1.00/ 1.00	0	1.49 ± 1.18 ***	0.00/ 4.00	1.00
–0.97 ± 4.85	–16.00/ 6.50	0	0.00 ± 2.37	–6.00/ 4.00	0	–0.97 ± 5.10	–15.00/ 7.00	–0.50
–2.20 ± 5.11 *	–11.50/ 8.50	–3.00	1.23 ± 1.69 ***	–2.00/ 4.80	1.00	–0.97 ± 4.67	–10.50/ 8.50	–2.00
–1.53 ± 2.60 **	–7.00/ 5.00	–1.50	0.18 ± 1.15	–4.00/ 4.00	0	–1.35 ± 2.26 **	–6.00/ 3.00	–1.00
–1.19 ± 0.62 ***	–2.00/ 0.00	–1.00	0.17 ± 0.34 ***	0.00/ 1.00	0	–1.02 ± 0.69 ***	–2.00/ 0.70	–1.00
–0.84 ± 0.75 ***	–2.00/ 0.00	–1.00	0.23 ± 0.40 **	0.00/ 1.00	0	–0.61 ± 0.80 ***	–2.00/ 0.50	–0.50
–0.70 ± 0.56 ***	–2.00/ 0.00	–0.50	0.18 ± 0.38 *	0.00/ 1.50	0	–0.52 ± 0.57 ***	–1.30/ 1.50	–0.50

described herein offers ease-of-use to the orthodontist and is nontraumatic for the patient. As build-ups are bonded to the molars, they do not need any patient participation, and they are fairly comfortable. Potential problems arising from the use of build-ups consist of caries, loss of the resin block, patient discomfort, and lingual inclination of molars. Only a small number of the build-ups failed, obtaining a breakdown rate of 3.8%. Lingual inclinations were minimized by placing the elevations on functional cusps, thus focusing occlusal forces on them and using overexpanded as well as rigid stainless steel 0.021 × 0.028-inch archwires. No other complication occurred during our experience with build-ups.

Other treatment alternatives such as multiloop or curved archwires have been proven to close the AOB only by extruding the incisors. They do not present any favorable skeletal or molar changes. By treating open bite malocclusion with build-ups, successful outcomes can be achieved by combining dental and skeletal corrections. Moreover, due to plastic retainers' being adjusted to avoid anterior contacts, molar intrusion can be maintained.

One limitation of the present study was its failure to register patient habits that could cause relapse, such as atypical deglutition.

Nevertheless, build-ups would appear to be a perfect alternative for correcting AOB malocclusion because of their convenience for both patient and orthodontist. Moreover, treatment outcomes and long-term stability have been found to be highly satisfactory.

CONCLUSIONS

- Posterior build-ups provide good results when treating skeletal open bite in adults.
- Dental and skeletal changes can be achieved and maintained by combining this resin elevation with fixed orthodontic appliances.

- Statistically significant improvements to open bite, mandibular plane angle, AFH, PP-MP, and molar intrusion values were observed after treatment, showing some relapse after the retention period.
- Overall correction was statistically significant and long-term stability clinically acceptable.

REFERENCES

1. Nielsen IL. Vertical malocclusions: etiology, development, diagnosis and some aspects of treatment. *Angle Orthod.* 1991;61:247–260.
2. Ng CS, Wong WK, Hagg U. Orthodontic treatment of anterior open bite. *Int J Paediatr Dent.* 2008;18:78–83.
3. Kim YH. Overbite depth indicator with particular reference to anterior open-bite. *Am J Orthod.* 1974;65:586–611.
4. López-Gavito G, Wallen TR, Little RM, Joondeph DR. Anterior open-bite malocclusion: a longitudinal 10-year postretention evaluation of orthodontically treated patients. *Am J Orthod.* 1985;87:175–186.
5. Bell WH, Creekmore TD, Alexander RG. Surgical correction of the long face syndrome. *Am J Orthod.* 1977;71:40–67.
6. Deguchi T, Kurosaka H, Olkawa H, et al. Comparison of orthodontic treatment outcomes in adults with skeletal open bite between conventional edgewise treatment and implant-anchored orthodontics. *Am J Orthod Dentofacial Orthop.* 2011;139:S60–S68.
7. Sarver DM, Weissman SM. Nonsurgical treatment of open bite in nongrowing patients. *Am J Orthod Dentofacial Orthop.* 1995;108:651–659.
8. Huang GJ. Long-term stability of anterior open-bite therapy: a review. *Semin Orthod.* 2002;8:162–172.
9. Greenlee GM, Huang GJ, Chen SS, Chen J, Koepsell T, Hujuel P. Stability of treatment for anterior open-bite malocclusion: a meta-analysis. *Am J Orthod Dentofacial Orthop.* 2011;139:154–169.
10. Baek MS, Choi YJ, Yu HS, Lee KJ, Kwak J, Park YC. Long-term stability of anterior open-bite treatment by intrusion of maxillary posterior teeth. *Am J Orthod Dentofacial Orthop.* 2010;138:396.e1–e9.
11. Kim YH. Anterior open bite and its treatment with multiloop edgewise archwire. *Angle Orthod.* 1987;57:290–321.

12. Endo T, Jojima K, Kobayashi Y, Shimooka S. Cephalometric evaluation of anterior open-bite nonextraction treatment, using multiloop edgewise archwire therapy. *Odontology*. 2006;94:51–58.
13. Carano A, Machata W, Siciliani G. Noncompliant treatment of skeletal open bite. *Am J Orthod Dentofacial Orthop*. 2005;128:781–786.
14. Hart TR, Cousley RRJ, Fishman LS, Tallents RH. Dentoskeletal changes following mini-implant molar intrusion in anterior open bite patients. *Angle Orthod*. 2015;85:941–948.
15. Erverdi N, Keles A, Nanda R. The use of skeletal anchorage in open bite treatment: a cephalometric evaluation. *Angle Orthod*. 2004;74:381–390.
16. De Clerck H, Geerinckx V, Siciliano S. The Zygoma Anchorage System. *J Clin Orthod*. 2002;36:455–459.
17. Sherwood K, Burch J, Thompson W. Closing anterior open bites by intruding molars with titanium miniplate anchorage. *Am J Orthod Dentofacial Orthop*. 2002;122:593–600.
18. Aras A. Vertical changes following orthodontic extraction treatment in skeletal open bite subjects. *Eur J Orthod*. 2002;24:407–416.
19. Proffit WR, Bailey LJ, Philips C, Turvey TA. Long-term stability of surgical open-bite correction by Le Fort I osteotomy. *Angle Orthod*. 2000;70:112–117.
20. De Barros RT, Câmara PP, Aloise AC, Siqueira DF, Paranhos LR, Torres FC. Anterior open bite correction using bite block: a case report. *Int J Orthod Milwaukee*. 2012;23:11–15.
21. Visiedo-Berni JL. Aplicación de resinas directas al esmalte. Los build-up. *Ortodoncia Española*. 1993;34:244–270.
22. Franchi L, Baccetti T, McNamara JA Jr. Mandibular growth as related to cervical vertebral maturation and body height. *Am J Orthod Dentofacial Orthop*. 2000;118:335–340.
23. Scheideman GB, Bell WH, Legan HL, Finn RA, Reisch JS. Cephalometric analysis of dentofacial normals. *Am J Orthod*. 1980;78:404–420.